



PATIENT

Shadow Carpenter

SPECIES

Feline

BREED

Snowshoe

SEX

MN

AGE

17 years

WEIGHT

6 kg

INTERPRETED BY

Remo Lobetti, BVSc,
MMedVet (Med),
PhD, Dipl. ECVIM

**IMAGING
PERFORMED BY**

Brent Crutchfield,
DVM

HOSPITAL NAME

Treasure Coast
Animal Emergency

REFERRING VET

Dr Cail

INVOICE

302965

DATE

5/16/22

PRESENTING CLINICAL SIGNS

History: N/A.

Physical Examination: N/A.

Urinalysis: N/A.

CBC: N/A.

Serum Biochemistry: N/A.

Radiographic Findings: N/A.

ULTRASONOGRAPHIC EXAMINATION OF THE ABDOMEN

Urinary System

Full urinary bladder a normal thickness (0.2 cm) and appearance of the wall. Normal anechoic urine with no sediment or uroliths evident.

Normal trigone area, proximal urethra, and iliac blood vessels.

Normal iliac lymph nodes. Ureters not visualized.

Normal renal size (left 3.8 cm, right 3.7 cm) with increased echogenic appearance, some loss of cortico-medullary differentiation, and normal pelvis and capsule.

Reproductive System

N/A.

Adrenal Glands

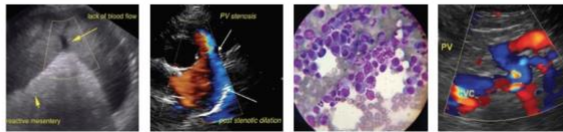
Normal shape, echogenic appearance, size, and position. Left 0.52 cm, right 0.38 cm.

Spleen

Enlarged (1 cm) with a diffuse hyperechogenic appearance. Smooth homogenous parenchyma, smooth curvi-linear capsule, and normal vasculature. No evidence of inflammatory, neoplastic, infarction, or infiltrative changes noted.

Liver

Normal size, echogenic appearance, and portal markings. No nodules or masses evident. Small gall bladder containing normal anechoic bile. Normal thickness and appearance of the gall bladder wall. Normal bile duct (0.1 cm).



PATIENT

Shadow Carpenter

SPECIES

Feline

BREED

Snowshoe

SEX

MN

AGE

17 years

WEIGHT

6 kg

INTERPRETED BY

Remo Lobetti, BVSc,
MMedVet (Med),
PhD, Dipl. ECVIM

IMAGING PERFORMED BY

Brent Crutchfield,
DVM

HOSPITAL NAME

Treasure Coast
Animal Emergency

REFERRING VET

Dr Cail

INVOICE

302965

DATE

5/16/22

Gastrointestinal

Normal appearance of the gastro-esophageal junction, stomach, duodenum, ileo-cecal junction, and colon with no loss of layering, normal wall thickness (stomach 0.32 cm, duodenum 0.29 cm, colon 0.12 cm) and peristalsis, and no distension of the lumen. Segmental thickening of the small intestine (up to 0.34 cm) with no loss of layering or distension of the lumen. Fecal material within the colon.

Pancreas

Enlarged and irregular with a hypoechogenic and nodular appearance. Irregular capsule. Hyperechogenic appearance of the mesentery and fat surrounding the pancreas.

Free Abdomen

Mesenteric lymphadenomegaly with an irregular shape and hypoechogenic appearance
No ascites.

ULTRASONOGRAPHIC FINDINGS

Primary findings:

- Splenic pathology.
- Pancreatitis.
- Mesenteric lymphadenomegaly.
- Enteropathy

Secondary findings:

- Age-related renal changes.

INTERPRETATION OF THE FINDINGS & FURTHER RECOMMENDATIONS

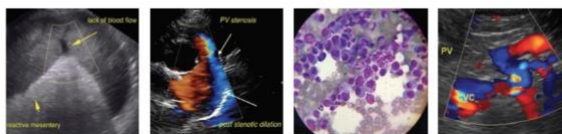
Etiologies for the spleen and lymph nodes would be reactive, hyperplasia, splenitis/lymphadenitis, and infiltrative neoplasia.

The appearance of the pancreas is consistent with pancreatitis with neoplasia, a differential diagnosis.

Etiologies for the enteropathy would be non-specific enteritis (dietary indiscretion, viral, bacterial, protozoal, helminths, toxins), inflammatory bowel disease, dietary hypersensitivity, and emerging lymphoma.

Further assessment needs to be based on the presenting clinical signs but could include fecal analysis, serum biochemistry, T4 assay, fPL/PSL assay, cobalamin assay, FNA cytology of the spleen, lymph nodes and pancreas, and endoscopy of the upper GI tract with biopsies.

Specific therapy would be dependent on an etiological diagnosis



PATIENT

Shadow Carpenter

SPECIES

Feline

BREED

Snowshoe

SEX

MN

AGE

17 years

WEIGHT

6 kg

INTERPRETED BY

Remo Lobetti, BVSc,
 MMedVet (Med),
 PhD, Dipl. ECVIM

IMAGING PERFORMED BY

Brent Crutchfield,
 DVM

HOSPITAL NAME

Treasure Coast
 Animal Emergency

REFERRING VET

Dr Cail

INVOICE

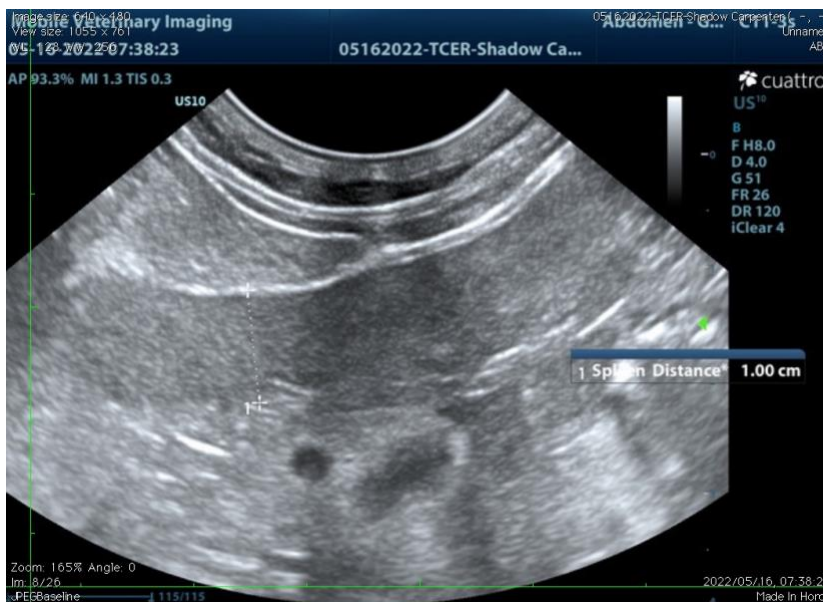302965

DATE

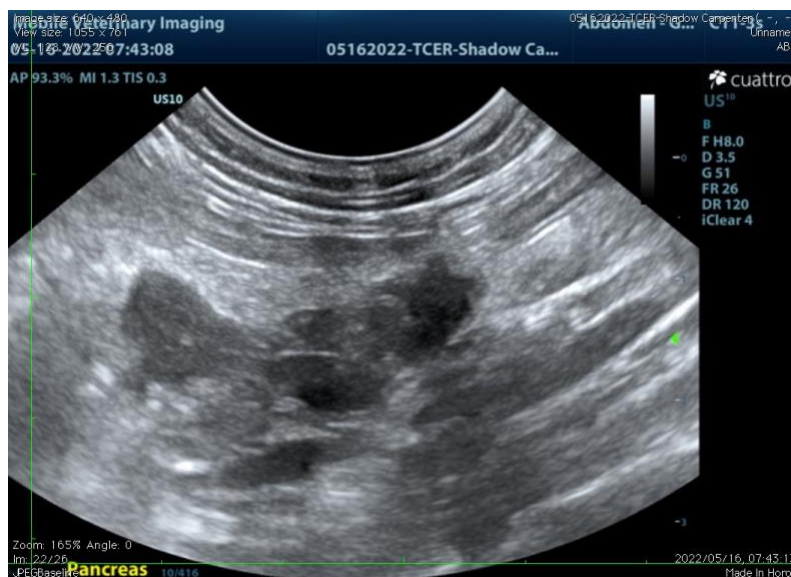
5/16/22

IMAGES

Spleen



Pancreas





PATIENT

Shadow Carpenter

SPECIES

Feline

BREED

Snowshoe

SEX

MN

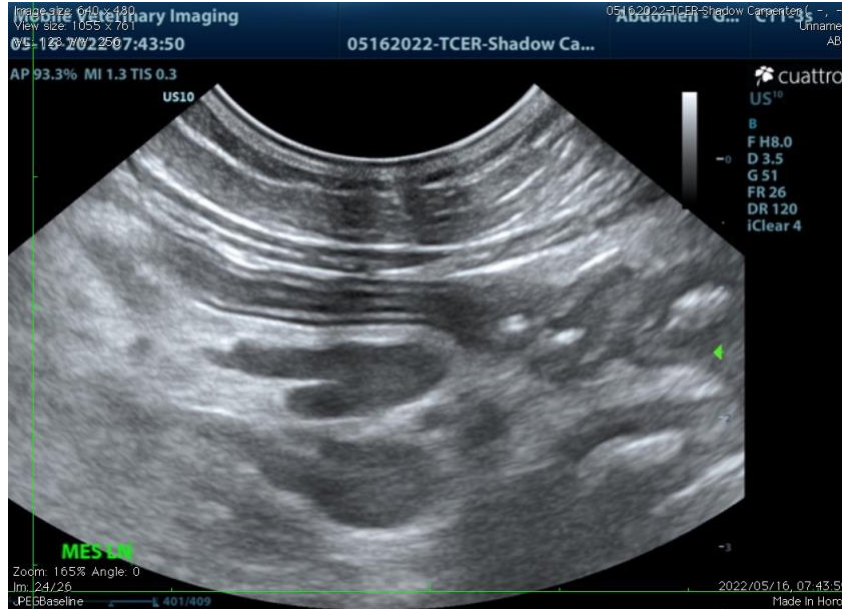
AGE

17 years

WEIGHT

6 kg

Lymph nodes



INTERPRETED BY

Remo Lobetti, BVSc,
MMedVet (Med),
PhD, Dipl. ECVIM

IMAGING PERFORMED BY

Brent Crutchfield,
DVM

HOSPITAL NAME

Treasure Coast
Animal Emergency

REFERRING VET

Dr Cail

INVOICE

302965

DATE

5/16/22

The information and recommendations provided are based on the images presented by the referring veterinarian. No evaluation can be communicated regarding pathology that was not visible in the image/video clips provided.

Thank you for this referral. If the clinical or image interpretation does not parallel your findings or if I can be of any further assistance please contact me.

Remo Lobetti, BVSc, MMedVet (Med), PhD, Dipl. ECVIM (Internal Medicine)
rlobetti@mweb.co.za